

Case Background

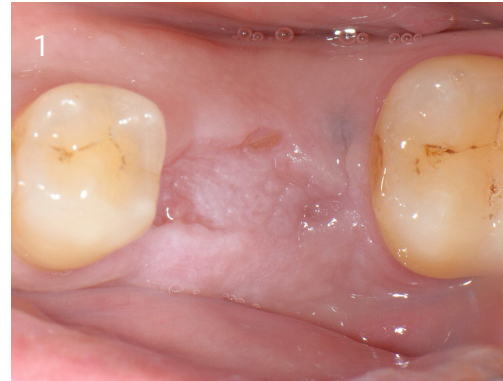
60 year male

Non-smoker

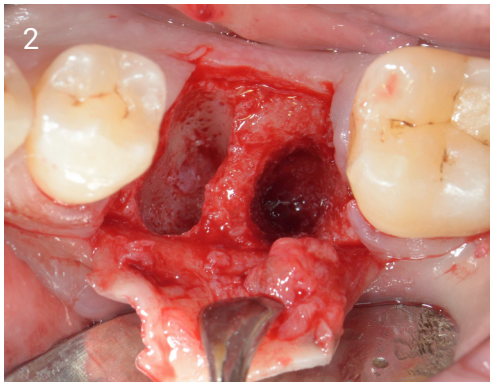
Residual root following extraction of lower left first molar

No sign of infection

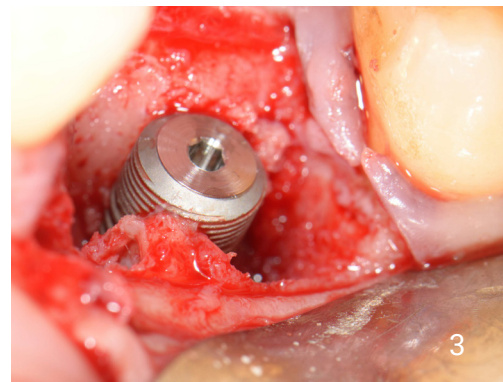
Case performed by Dr Minas Leventis, University of Athens, Greece



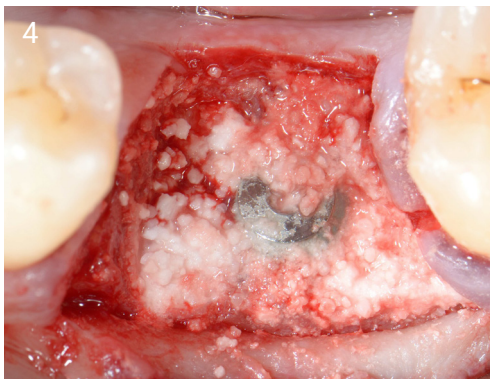1. Clinical view four weeks after extraction.



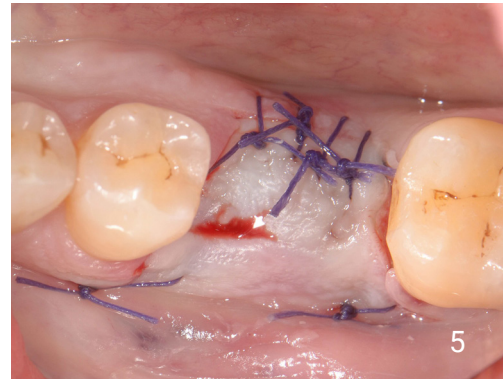2. Clinical view after extraction of the root and thorough debridement of the site.



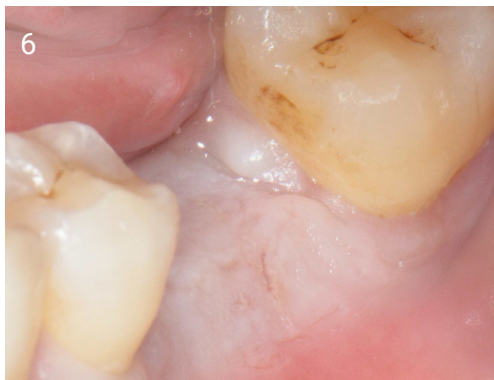3. Implant placed at the correct 3D positioning. Note the bone defect between the implant surface and the surrounding bone walls.



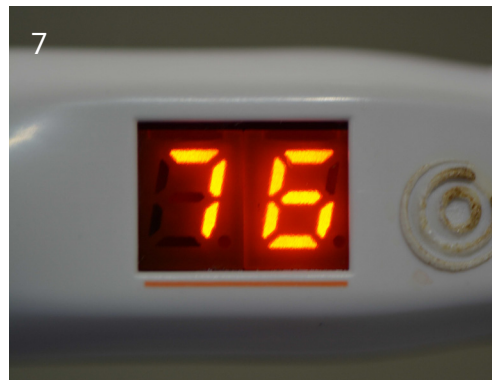4. Bone grafting with EthOss®.



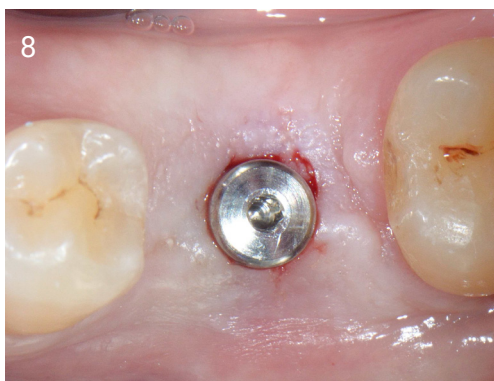
5. Tension free closure.



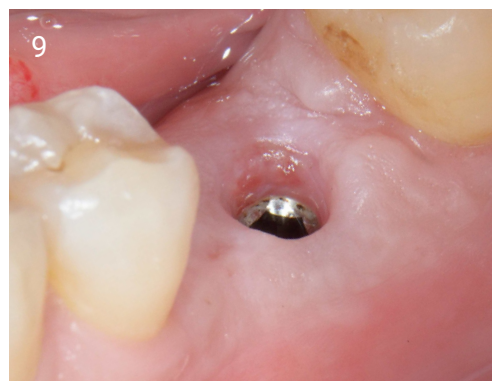6. Clinical view after 10 weeks.



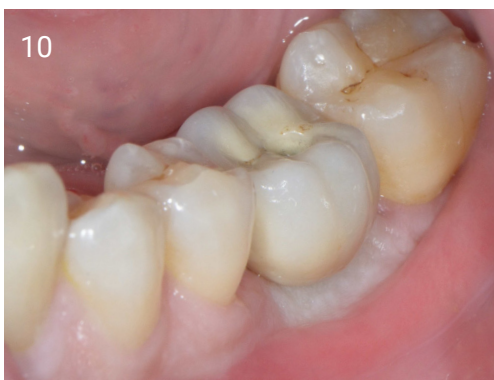7. ISQ measurement showing high secondary implant stability.



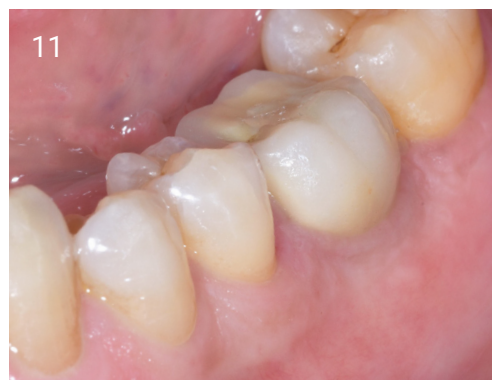8. Occlusal view after placing of the healing abutment.



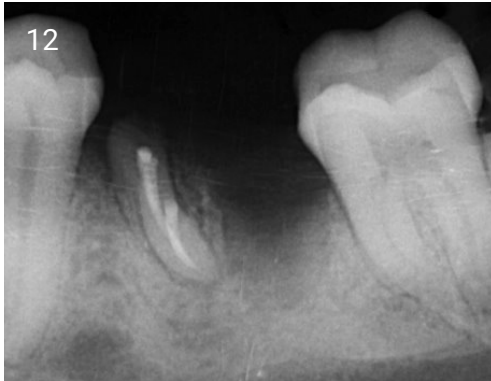
9. Maturation of the soft tissues 2 weeks after placement of the healing abutment.



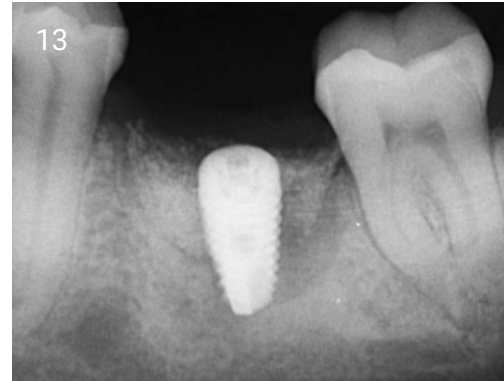
10. Screw-retained metal-ceramic crown fitted and torqued at 35Ncm.



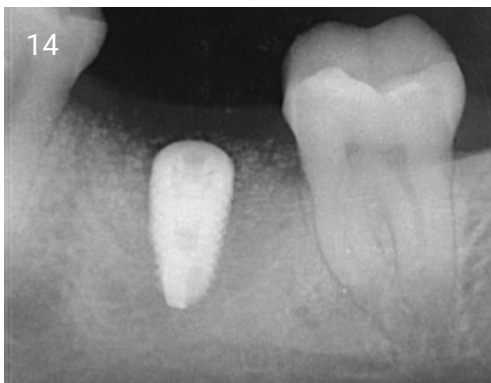11. Clinical view one year after loading of the implant.



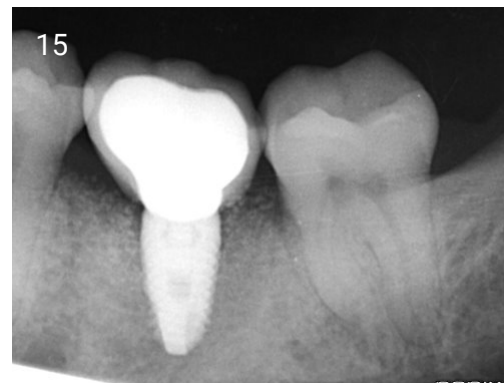
12. Initial x-ray.



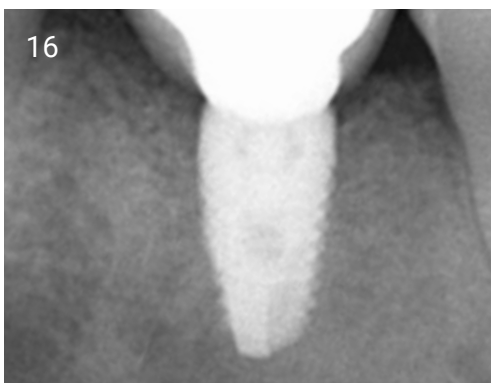13. Periapical radiograph immediately after implant placement and bone grafting.



14. X-ray 10 weeks after implant placement and grafting showing the consolidation of the grafting material around the implant.



15. X-ray immediately after fitting the implant crown.



16. X-Ray one year after loading of the implant.

Case originally printed in the European Journal for Dental Implantologists, Vol 13, Issue 2/2017.