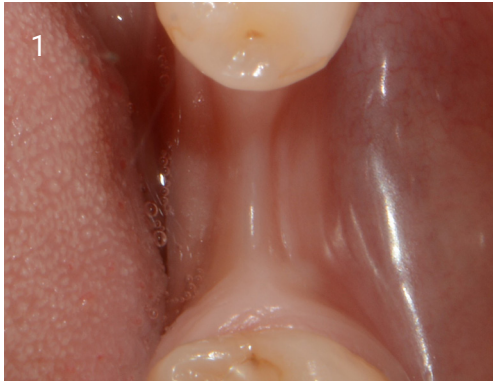
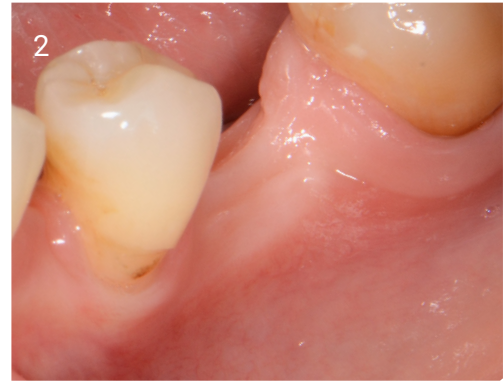

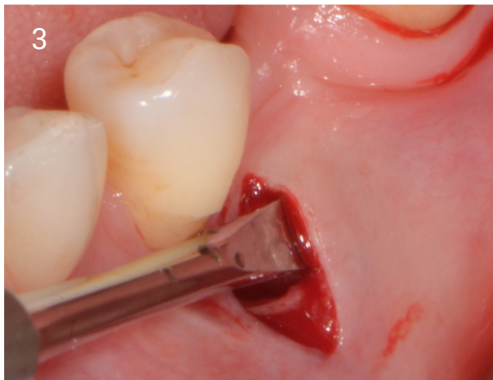TUNNEL GRAFT CASE STUDY



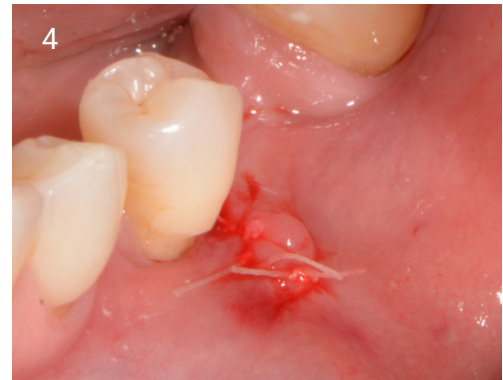1. Narrow ridge due to modelling.



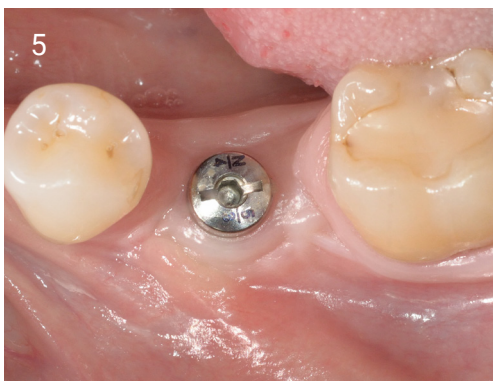2. Narrow ridge and reduced keratinized gingiva.



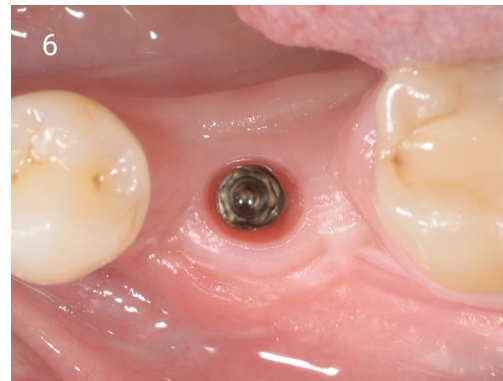3. Incision distal to 5, periosteum lifted.



4. EthOss® placed with graft gun and sutured closed.

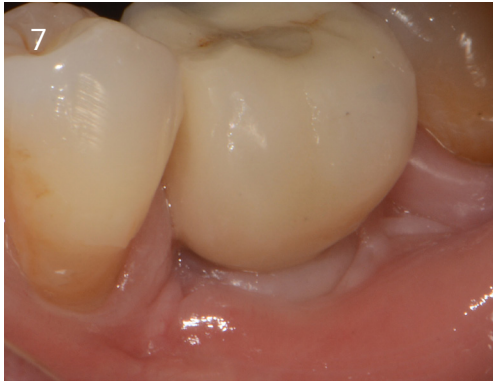

5. Implant placed 10 weeks following graft. Image shows healing at 10 weeks following implant placement.

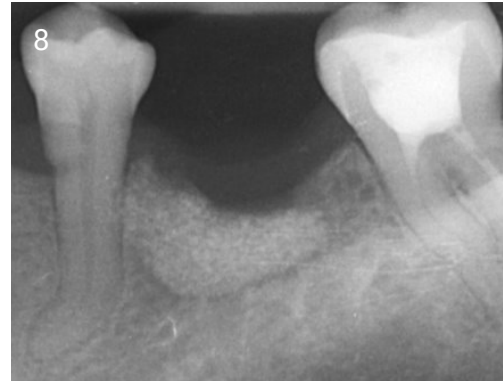

6. Also 10 weeks following implant placement, cap removed to take impression, there was no soft tissue grafting. 75 ISQ reading.

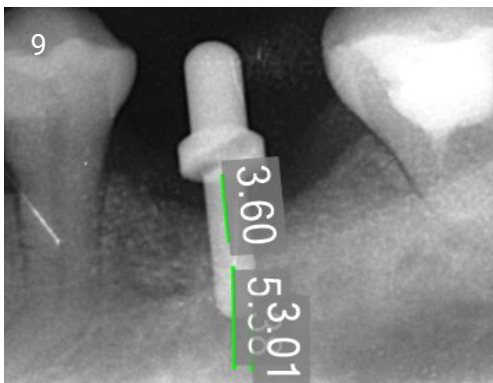
TUNNEL GRAFT CASE STUDY



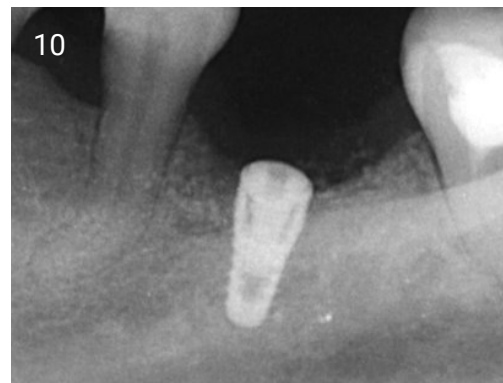7. Fitted 9 months.



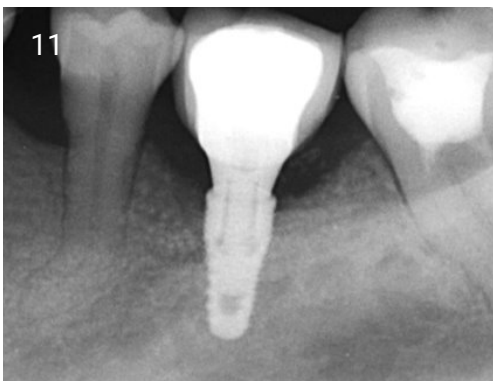8. Radiograph of graft in-situ.



9. Assessment of implant placement (10 weeks following graft).



10. Radiograph of implant placed (10 weeks following graft).



11. Loaded 9 months.