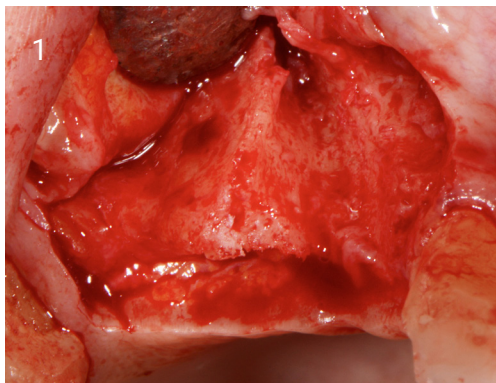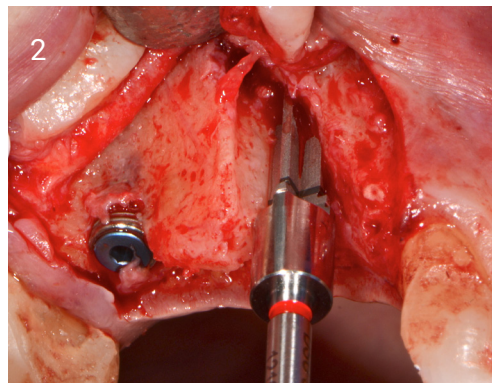
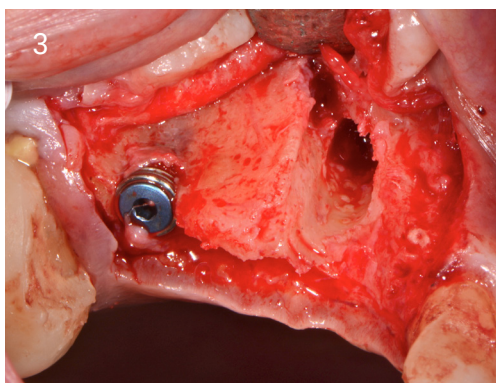


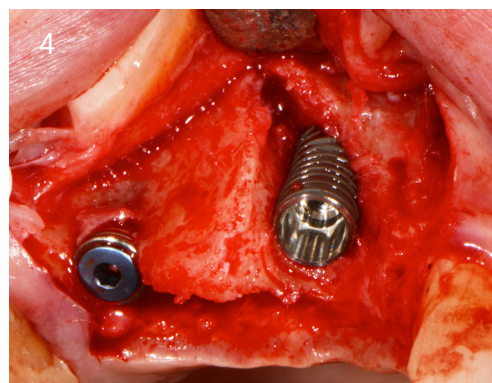
1. Buccal defect at the 13 area.



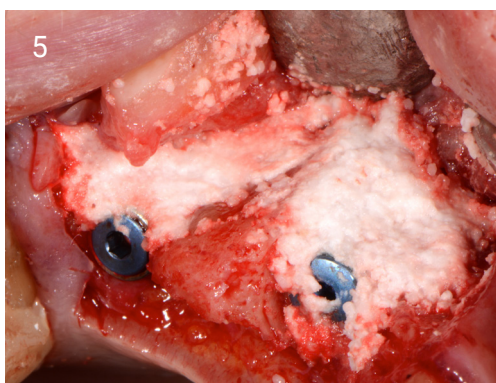
2. Angle placement drill.



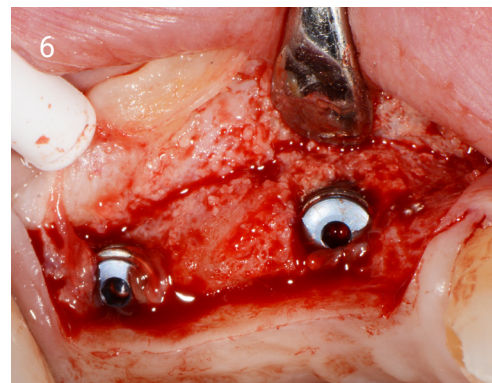
3. Angled osteotomy.



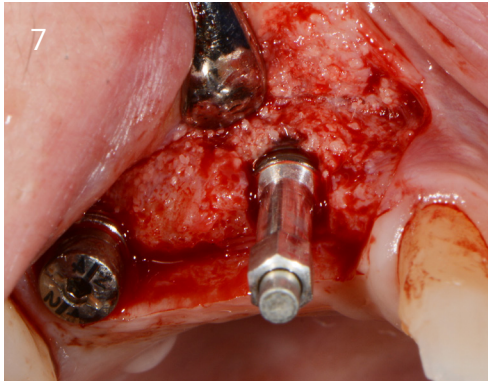
4. Implant placed.



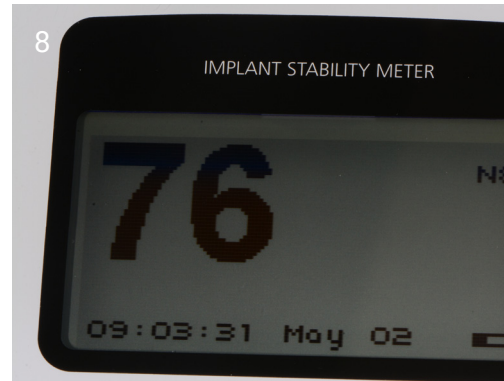
5. Grafted with EthOss[®].



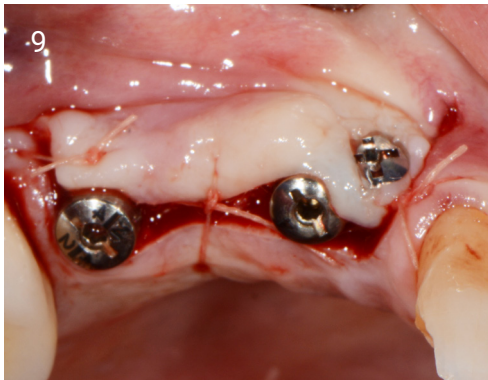6. New bone at 13 weeks.



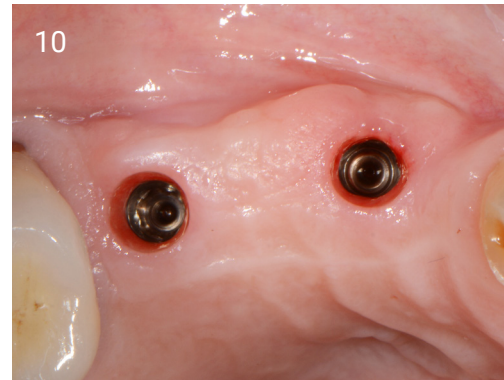
7. Osstell peg.



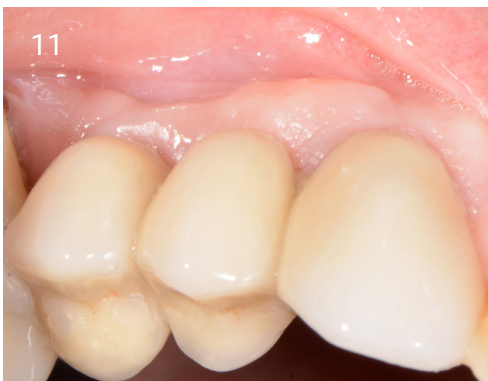8. Osstell reading of 76 ISQ.



9. Soft tissue screw tissue adjustment.



10. Impressions.



11. Loaded at 2 years.