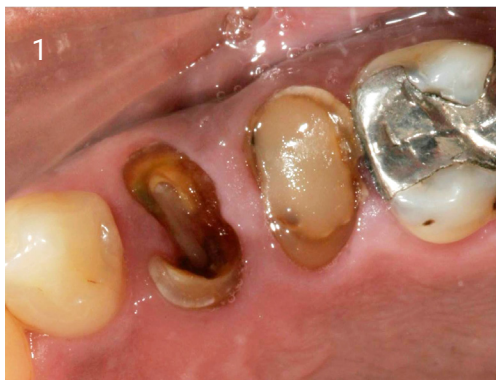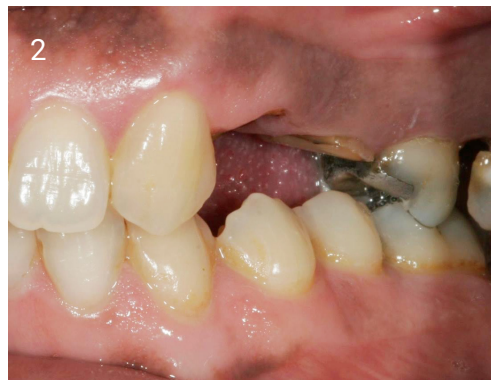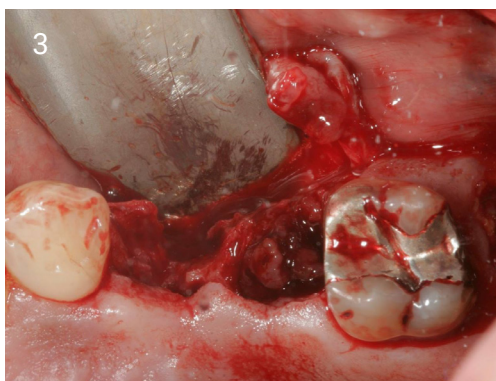




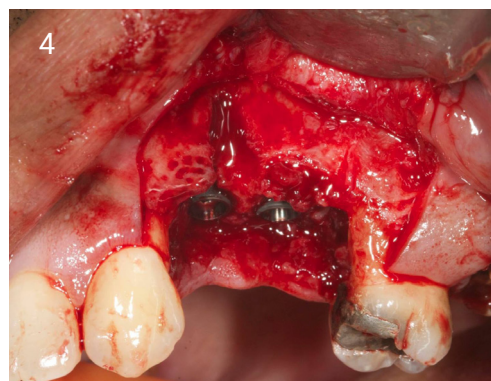
1. Failing 24 & 25 with chronic apical granulomas.



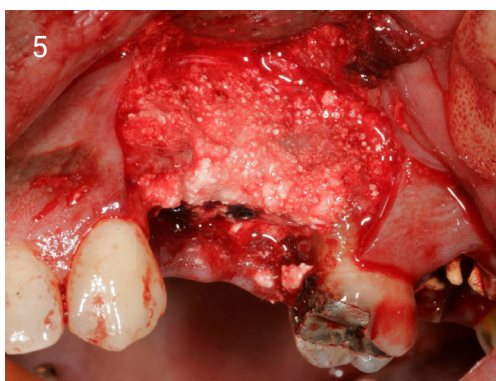
2. Buccal profile view.



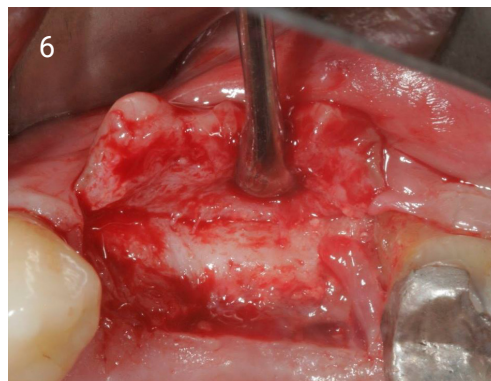
3. Upon removal of teeth, buccal plate non existent at UL4. Type II (ITI) approach with re-entry after 4 weeks. Granulation tissue removed down to solid bone.



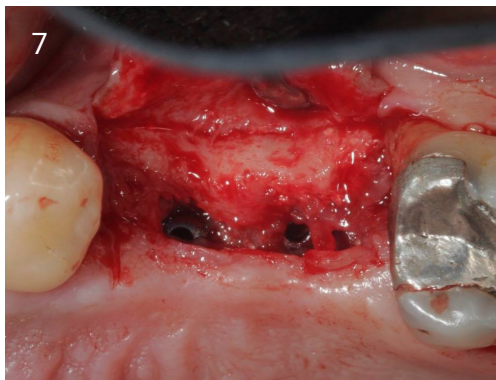
4. Implants placed.



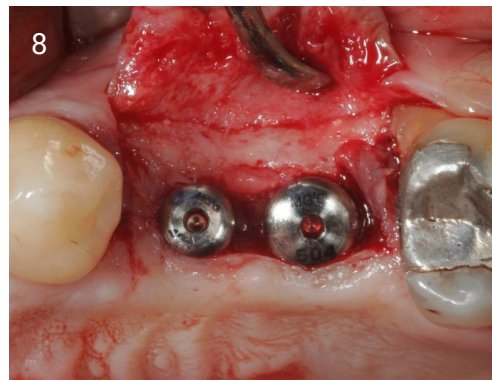5. EthOss[®] placed and, in this case, over contoured both buccally and vertically.



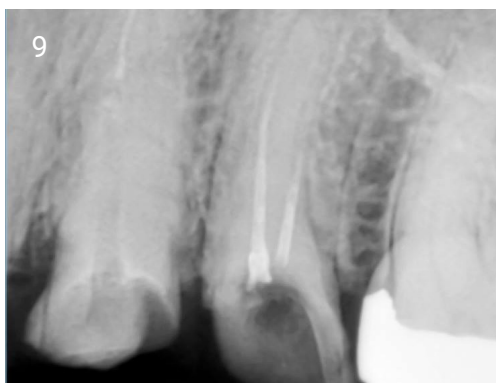6. Site exposed at 12 weeks. New bone grown over the top of the cover screws where the EthOss[®] was over contoured.



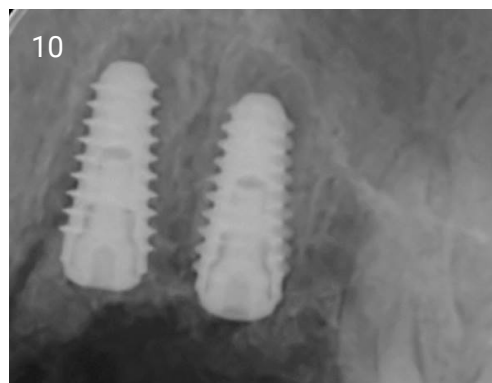7. Site after bone removal to reveal implant cover screws.



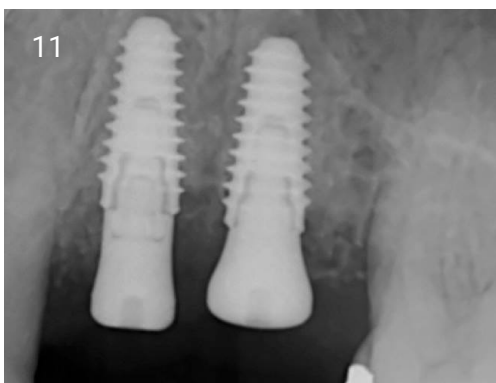
8. 4mm high healing abutments fitted. Image clearly shows a significant improvement in buccal bone width and profile.



9. Pre-op radiograph.



10. Immediate post-op radiograph.



11. Significant changes to bone density evident post-operatively (20 weeks).