

## Case Background

Female

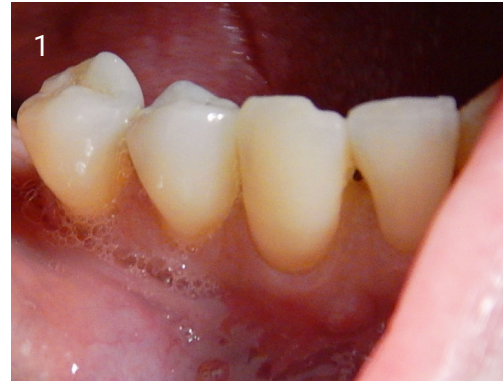54 years old

Periodontitis in tooth 43  
has caused bone loss

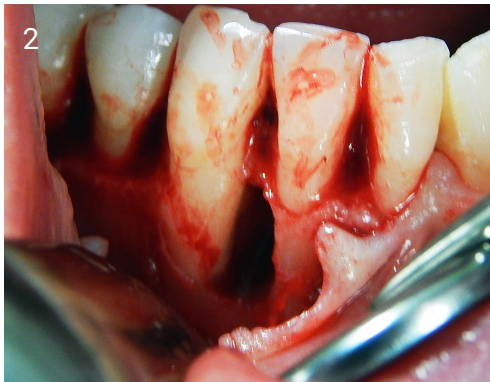
Loosening of teeth: 3mm

Pocket depth: 9mm

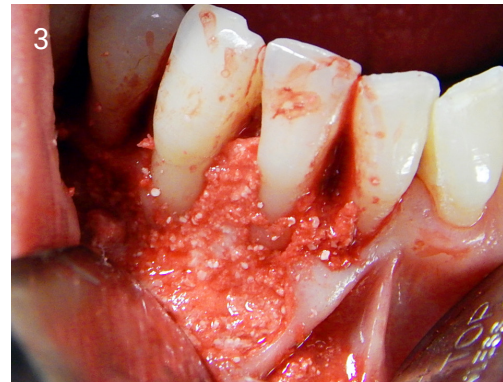*Case performed by Dr Manuel Bras  
Da Silva, Lünen, Germany*



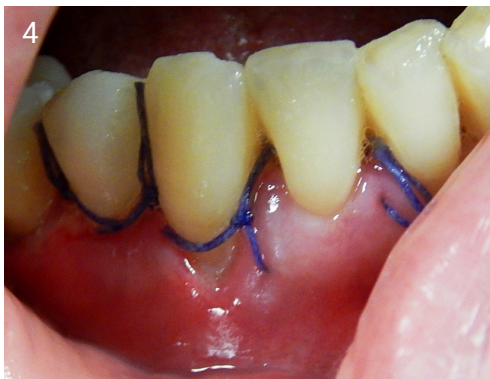1. Pre-op view.



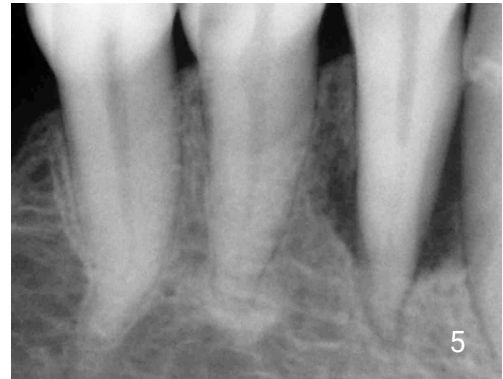2. Severe bony defect.



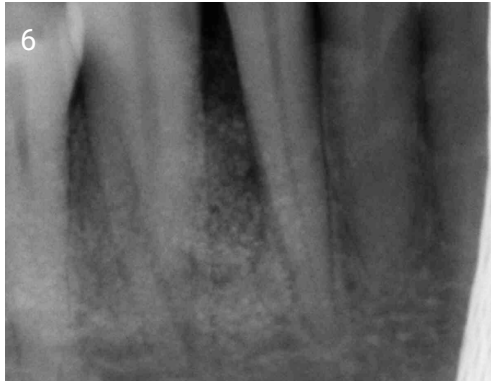
3. Grafted with EthOss®, allowed to set for 3 minutes.



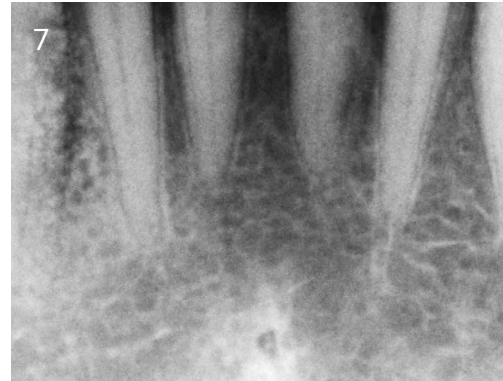
4. Sutured closed after graft material has set.



5. X-ray showing defect, before grafting.



6. X-ray immediately after grafting with EthOss®.



7. X-ray after 1 year showing new host bone.

### **Results after 12 months**

Loosening of the teeth:  
0-1mm

Pocket depth: 4mm

No complications in  
healing

Patient reports no pain